

A case report of neonatal COVID-19 infection in China

Shaoshuai Wang¹, Lili Guo¹, Ling Chen², Weiyong Liu³, Yong Cao⁴, Jingyi Zhang^{1*}, Ling Feng^{1*}

1. Department of Obstetrics and Gynecology, Tongji Hospital, Tongji Medical College, Huazhong University of Science and Technology, Wuhan, China.

2. Department of Pediatrics, Tongji Hospital, Tongji Medical College, Huazhong University of Science and Technology, Wuhan, China.

3. Department of Laboratory Medicine, Tongji Hospital, Tongji Medical College, Huazhong University of Science and Technology, Wuhan, China.

4. Department of Infectious Disease, Tongji Hospital, Tongji Medical College, Huazhong University of Science and Technology, Wuhan, China.

*JZ and LF contributed equally

Correspondence:

Ling Feng. Email: fltj007@163.com

Abstract

In December 2019, the 2019 novel coronavirus disease (COVID-19) caused by SARS-CoV-2 emerged in China and now has spread in many countries. Pregnant women are susceptible population of COVID-19 which are more likely to have complications and even progress to severe illness. We report a case of neonatal COVID-19 infection in China with pharyngeal swabs tested positive by rRT-PCR assay 36 hours after birth. However, whether the case is a vertical transmission from mother to child remains to be confirmed.

Background

In December 2019, a pneumonia caused by 2019 novel coronavirus (SARS-CoV-2) emerged in Wuhan, Hubei Province. Since COVID-19 is highly contagious with a certain mortality rate, it was classified as a class B infectious disease and was managed as a Class A infectious disease in China in January 2020[1]. China has taken strict infection control measures, isolated the exposed and suspected cases according to international standards, constantly updated the diagnosis and treatment process and carried out public education [2].

SARS-CoV-2, along with severe acute respiratory syndrome coronavirus (SARS-CoV) and Middle East respiratory syndrome (MERS-CoV), all belong to β - coronavirus. In the past 20 years, SARS-CoV and MERS-CoV have caused more than 10,000 infected patients worldwide. The mortality rate of SARS-CoV infection is 10%, of which the mortality rate of SARS-CoV infection in pregnant women is 25%, and the mortality rate of MERS-CoV infection is up to 37% [3-6]. Pregnant women are susceptible population of SARS-CoV-2 which are more likely to have complications and even progress to severe illness. There is not enough data to determine the effect of COVID-19 infection on the fetus. Whether COVID-19 has mother-to-child vertical transmission and its short-term and long-term harm to offspring is still unclear.

We report a case of neonatal COVID-19 infection in China with pharyngeal swabs tested positive by rRT-PCR assay 36 hours after birth. However, whether the case is a vertical transmission from mother to child remains to be confirmed.

Case presentation

The mother of the neonatal patient is a 34-year-old pregnant woman who lives near the Huanan Seafood Wholesale Market (about 1.2km walking distance) in Wuhan. She has not been to the market during pregnancy and her family has no confirmed or suspected cases of COVID-19, but more than 15 people had been diagnosed in the same community she lives in. She has a history of hypothyroidism for 4 years and has been treated with oral drugs, with no history of hypertension, diabetes, or heart disease. She had a terminal of pregnancy due to chromosome abnormalities in 2016. She is allergic to penicillin and first-generation cephalosporin (positive in skin test).

At 20:00 on February 1, 2020, the 40-week gestation pregnant woman developed small amount of per vaginal bleeding and lower abdominal pain. Two hours later, she developed a fever (37.8 °C) and attended to Wuhan women and children medical care center for medical advice. As she was febrile, she was referred to the fever clinic of Wuhan Tongji Hospital the next morning. Thoracic computerized tomography scan showed ground-glass opacities in the left upper and lower lobes, indicating the possibility of viral pneumonia (Fig. 1). Blood tests revealed lymphopenia ($0.97 \times 10^9/L$, normal: $1.1-3.2 \times 10^9/L$), neutrophilia ($9.97 \times 10^9/L$, normal: $1.8-6.3 \times 10^9/L$), and elevated hs-CRP level (11.5mg/L, normal: <1 mg/L). She was hospitalized for suspected viral pneumonia

On admission, her body temperature was 37.8 °C and her blood pressure was 131/89 mmHg, with respiratory rate of 20 breaths per minute, pulse of 96 beats per minute. She had no cough or sputum. Fetal heart rate (FHR) was 136 bpm and fetal heart monitoring showed no abnormality. Emergency Cesarean section was performed. Meconium-stained liquor was noted intra-operatively. At 08:45, a baby boy was delivered, weighted 3205g. Apgar scores at 1 and 5 minutes were 8 and 9. The infant had no moaning or spitting after birth. The skin was ruddy and the crying was loud. The mother had been wearing an N95 mask throughout the operation, and the baby had no contact with the mother after birth. The infant was transferred to neonatology department 10 minutes after birth for close observation and the mother was transferred to the fever ward for isolation after surgery.

Half an hour after birth, the infant vomitted once after feeding formula, which we considered to be swallowing syndrome. After gastric lavage, the infant could be fed normally. Blood tests of the neonate revealed lymphopenia ($2.43 \times 10^9/L$, normal: $3-8 \times 10^9/L$), deranged liver function tests (AST 143U/L , normal: ≤ 41 U/L. TBIL 33.0 umol/L, normal: ≤ 26 umol/L. IBIL 26.0 umol/L, normal: ≤ 16.8 umol/L.) and elevated creatine kinase level (479 U/L , normal: ≤ 41 U/L). Intravenous penicillin G (15wu q.d, intravenous bolus) and vitamin K1 (1mg q.d, intravenously) were given as antibiotic prophylaxis and to prevent coagulopathy, respectively.

The mother was well and afebrile during the immediate post-operative period. She had no cough or any other discomfort such as diarrhea, nausea and vomiting. Her vital signs were stable with blood oxygen saturation of 99%. Antiviral treatment including 40 µg of recombinant human interferon α1b atomized inhalation with 2 mL of sterilization injection water was used twice a day, and ganciclovir (0.25 g every 12 h, intravenously). Abipenem

(0.3g every 12 h, intravenously) and moxifloxacin (0.4g q.d, intravenously) were used for anti-infection. The mother had intermittent fever on the first postoperative day with the highest temperature up to 38.3 ° C. She was given methylprednisolone (20mg intravenously). Her pharyngeal swab sampled for SARS-CoV-2 reported back as positive later that day. Pharyngeal swab specimen was collected immediately from the infant (36 hours after birth), along with the breast milk of the mother. We recommended the mother not to breastfeed and empty the breast milk to avoid mastitis.

The mental response of the newborn was acceptable the first day after birth and his blood oxygen saturation maintained above 92% without supplyment of oxygen. The laboratory results of the infant reported back as negative including *legionella pneumophila*, *chlamydia pneumoniae*, *mycoplasma pneumoniae*, *Q fever rickettsia*, *adenovirus*, *respiratory syncytial virus*, *influenza A virus*, *influenza B virus*, *parainfluenza virus 1 / 2 / 3*.

On February 4, the second day after the surgery, the mother's vitals were stable and she was given methylprednisolone (40mg q.d, intravenously). The neonate was well and his blood gas analysis showed: PH 7.476↑, PCO₂ 28.2 mmHg↓, PO₂ 116.0 mmHg↑, HCO₃-20.6 mmol/L↓, BE -1.30 mmol/L, SPO₂ 98.4%. A complete set of pediatric viruses results of the infant reported back as negative (including CMV, RV, TOX, HSV I, HSV II, ECHO, PVB19, EBV, CA16, CVB, MV, VZV). The neonatal chest x-ray showed thickened lung texture with no abnormalities in heart and palate (fig.2). The infant was given formula 25ml every 3 hours and he was closely monitored.

On February 5, the newborn's vital signs were stable with the blood oxygen saturation maintained above 90%, with no discomfort such as apnea or vomiting. The result of pharyngeal swab for SARS-CoV-2 was positive at 36 hours after birth. Combining all the laboratory results with fully discussion, we made a diagnosis that the infant was confirmed with SARS-CoV-2 infection. Since the neonatal department of Tongji Hospital did not have the isolation conditions for the diagnosed newborn, he was transferred to Wuhan Children's Hospital for further isolation later that day. After finding evidence of neonatal infection, we performed nucleic acid tests for SARS-CoV-2 on cord blood and placenta specimens that we retained during the operation, and the results were negative. The mother's breast milk sample was negative for SARS-CoV-2 as well.

We followed up the newborn's condition after he was transferred to Wuhan Children's Hospital. He was well and afebrile with no cough or vomiting. He was closely monitored in isolation and no special treatment was given. Chest CT on Feb 6 showed high-density nodular shadow under the pleura of the posterior segment of the upper lobe of the right lung. Chest CT on Feb 12 showed that the upper lobe and lower lobe of the right lung were scattered with small pieces of patchy shadow. Chest CT on Feb 17 showed that a few small pieces of patchy shadow in the upper lobe of the right lung, which were absorbed compared with the previous one. On February 17, 2020, the nucleic acid of pharyngeal swab and anal swab for SARS-CoV-2 were negative. The newborn was discharged on February 18, 2020.

Discussion

The severity of viral pneumonia in pregnancy is evidently related to physiological and immunological changes that result in a shift from cell-mediated to humoral-mediated immunity [7]. When pregnant women become infected with viral pneumonia, they are more likely to have complications and progress to severe cases [8]. A study in Hong Kong in 2004 shows that SARS during pregnancy is associated with high incidences of spontaneous miscarriage, preterm delivery, and intrauterine growth restriction[9]. Another study shows that pregnant women with pneumonia have an increased risk of developing low birth weight infants, preterm births, restricted fetal growth, and 5-minute Apgar score <7 compared to healthy pregnant women [10]. Although there have been no clinical or serological reports of SARS or MERS in neonatal infections in existing studies[9,17], evidence of vertical mother-to-child transmission in other respiratory viruses such as H1N1 and respiratory syncytial virus (RSV) have been reported[11].

There have been several studies concerning intrauterine vertical transmission potential of COVID-19 and its effects on newborns[12,13]. All the newborns of COVID-19 infected mothers in these cases were negative for nucleic acid test and one study shows that COVID-19 may have adverse effects on newborns, causing problems such as fetal distress, premature labor, respiratory distress, thrombocytopenia accompanied by abnormal liver function, and even death[13].

We report the first case of neonatal COVID-19 infection in China whose mother was confirmed with COVID-19. The clinical manifestations of the mother and the baby were both

mild and the baby's prognosis was well. Whether the case is intrauterine vertical transmission or not remains controversial. Although the results of nucleic acid detection of cord blood and placenta in this case are negative, which do not support the diagnosis of intrauterine transmission, but the possibility of vertical intrauterine transmission of SARS-CoV-2 is not ruled out. The reasons are as follows: 1) When the viral load is not high enough, the detection rate of existing methods is limited and false negatives may occur. Therefore, the negative results of umbilical cord blood and placental nucleic acid during the operation do not exclude the possibility of false negatives. 2) According to the clinical manifestations, the pregnant woman first had fever symptoms at 22:00 on February 1. However, the CT result after a few hours showed ground-glass opacities in the left upper and lower lobes, suggesting that the pregnant woman may have been asymptomatic in the early stage. Since we lack the data of maternal viral load, there is no evidence whether the fetus has been infected with maternal viremia in utero before the mother had any clinical manifestation. 3) In addition to this case, neonatal infections have been reported in other provinces and cities in China [14]. The possibility of mother-to-child transmission of SARS-CoV-2 cannot be ruled out.

We also discussed whether the newborn is a nosocomial infection. According to the No.225-Management Guidelines for Obstetric Patients and Neonates Born to Mothers With Suspected or Probable Severe Acute Respiratory Syndrome (SARS) [15], we took strict measures to reduce the risk of infection. The male infant in the case reported was delivered by emergency cesarean under contact, droplet, and airborne transmission precautions [16]. The newborn had early clamping of the umbilical cord and early cleansing to remove maternal blood and amniotic fluid. Then he was transferred to an isolation room in the neonatal nursery shortly after delivery. The mother wore a N95 mask during the operation and had no close contact with the newborn. However, since we did not retain the specimens of the newborn's pharyngeal swabs shortly after birth, the first time we took samples of the newborn's pharyngeal swabs was 36 hours after birth. During this period, we can not rule out the possibility of other contact transmission of newborn. In addition, it has been confirmed that SARS coronavirus was detected by RT-PCR in the maternal peritoneal fluid collected during cesarean section in 28 SARS patients [17], which reminds us that it is very important to shorten the delivery time of fetus and minimize the contact between fetus and maternal blood and body fluid during cesarean section.

Conclusion

Clinical datas on COVID-19 infection in newborns are still very limited. Whether SARS-CoV-2 can transmit vertically through placenta and its short-term and long-term harm to offsprings is still unclear. Therefore, it is important to keep all the specimens of SARS-CoV-2 infected and suspected pregnant women and their newborns, including pharyngeal swabs, peripheral blood, placenta tissue after delivery, amniotic fluid, cord blood, newborn pharyngeal swabs and breast milk, for in-depth study and continuous follow-up observation of future generations.

Declaration of interests

We declare no competing interests.

References

- [1] Data from the official website of the National Health Commission
(<http://www.nhc.gov.cn/>)
- [2]Lancet T. Emerging understandings of 2019-nCoV[J]. Lancet, 2020,DOI: 10.1016/S0140-6736(20)30186-0.
- [3]Ksiazek TG, Erdman D, Goldsmith CS, et al. A novel coronavirus associated with severe acute respiratory syndrome[J]. N Engl J Med, 2003,348(20):1953-1966. DOI: 10.1056/NEJMoa030781.
- [4]Zaki AM, van Boheemen S, Bestebroer TM, et al. Isolation of a novel coronavirus from a man with pneumonia in Saudi Arabia[J]. N Engl J Med, 2012,367(19):1814-1820. DOI: 10.1056/NEJMoa1211721.
- [5]World Health Organization. Summary of probable SARS cases with onset of illness from 1 November 2002 to 31 July 2003 [EB/OL]. (2004-04)[2020-01-19].https://www.who.int/csr/sars/country/table2004_04_21/en/.
- [6]World Health Organization. Middle East respiratory syndrome coronavirus (MERS-CoV). November, 2019[EB/OL]. 2019-11)[2020-01-25].<http://www.who.int/emergencies/mers-cov/en/>.
- [7] Ramsey PS, Ramin KD. Pneumonia in pregnancy. Obstet Gynecol Clin N Am. 2001;28(3):553–69.
- [8]Lam CM, Wong SF, Leung TN, et al. A case-controlled study comparing clinical course and outcomes of pregnant and non-pregnant women with severe acute respiratory syndrome. BJOG. 2004;111(8):771–4
- [9]Wong SF, Chow KM, Leung TN, et al. Pregnancy and perinatal outcomes of women with severe acute respiratory syndrome[J]. Am J Obstet Gynecol, 2004,191(1):292-297. DOI: 10.1016/j.ajog.2003.11.019.
- [10]Chen YH, Keller J, Wang IT, et al. Pneumonia and pregnancy outcomes: a nationwide population-based study[J]. Am J Obstet Gynecol, 2012,207(4):288.e1-7. DOI: 10.1016/j.ajog.2012.08.023.
- [11]Takahashi N, Kitajima H, Kusuda S, Morioka I, Itabashi K. Pandemic (H1N1) 2009 in Neonates, Japan. Emerg Infect Dis. 2011;17(9):1763–5.

[12] Chen H, Guo J, Wang C, et al. Clinical characteristics and intrauterine vertical transmission potential of 2019-nCoV infection in nine pregnant women: a retrospective review of medical records. *Lancet* 2020; published online Feb 12. [https://doi.org/10.1016/S0140-6736\(20\)30360-3](https://doi.org/10.1016/S0140-6736(20)30360-3).

[13] Zhu H, Wang L, Fang C, et al. Clinical analysis of 10 neonates born to mothers with 2019- nCoV pneumonia. *Transl Pediatr* 2020; published online Feb 10. <http://dx.doi.org/10.21037/tp.2020.02.06>.

[14] National Health Commission of the People's Republic of China. Transcript of Press Conference on Feb 7, 2020. <http://www.nhc.gov.cn/xcs/s3574/202002/5bc099fc9144445297e8776838e57ddc.shtml> (accessed Feb 7, 2020; in Chinese).

[15] Maxwell C, McGeer A, Tai KFY, Sermer M. No.225-Management Guidelines for Obstetric Patients and Neonates Born to Mothers With Suspected or Probable Severe Acute Respiratory Syndrome (SARS). *J Obstet Gynaecol Can.* 2017 Aug;39(8):e130-e137. doi: 10.1016/j.jogc.2017.04.024.

[16] Alserehi H, Wali G, Alshukairi A, Alraddadi B. Impact of Middle East Respiratory Syndrome coronavirus (MERS-CoV) on pregnancy and perinatal outcome. *BMC Infect Dis.* 2016 Mar 2;16:105. doi: 10.1186/s12879-016-1437-y.

[17] Shek CC, Ng PC, Fung GPG, et al. Infants born to mothers with severe acute respiratory syndrome (SARS). *Pediatrics.* 2003 Oct;112(4):e254.

Figures:

Figure 1: Chest CT obtained on February 2, 2020. Chest CT showed signs of infection in the left upper and lower lobe, indicating the possibility of viral pneumonia, with limited emphysema in the right lower lobe and a little cord focus in the right middle lobe.

Figure 2: Chest x-ray of the newborn obtained on February 4, 2020. Chest x-ray showed thickened lung texture with no abnormalities in heart and palate.

Figure 1

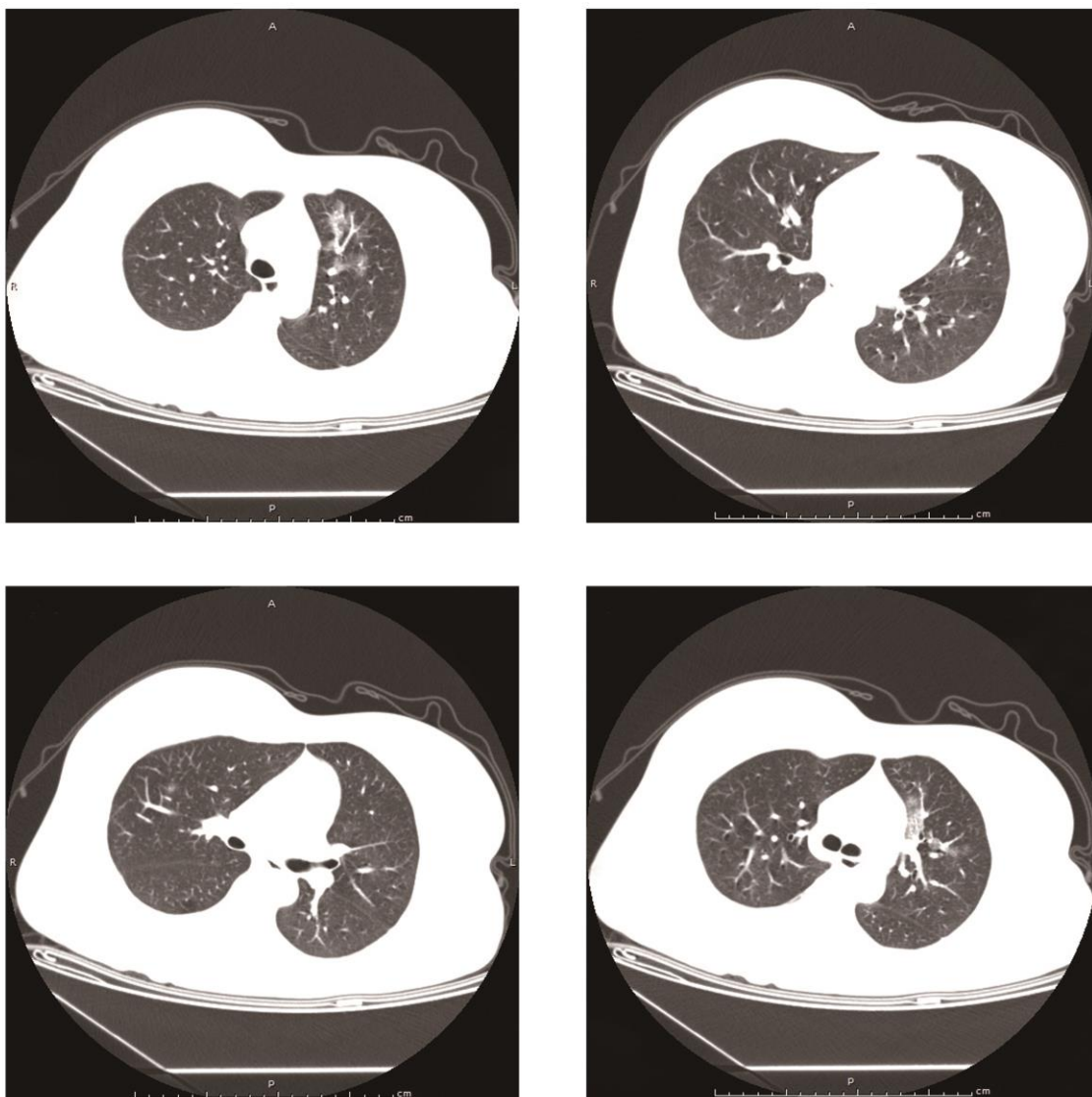


Figure 2

